SJIF Impact Factor: 5.464

WORLD JOURNAL OF ADVANCE HEALTHCARE RESEARCH

ISSN: 2457-0400
Volume: 4.
Issue: 2.
Page N. 159-163
Year: 2020

Case Report www.wjahr.com

MALE BREAST CANCER: A CASE REPORT AND REVIEW OF LITERATURE

Dr. Akpor I. O.*[1], Vhriterhire R. A.[1], Ngbea J. A.[1], Ojo B. A.[1], Eke B. A.[2], Nyaga T.[1], Gyenger D.[1]

[1]Department of Anatomical Pathology, College of Health Sciences, Benue State University Makurdi, NorthCentral Nigeria.
[2]Department of General Surgery, College of Health Sciences, Benue State University, Makurdi, NorthCentral Nigeria.

Received date: 28 January 2020 **Revised date:** 18 February 2020 **Accepted date:** 08 March 2020

***Corresponding author: Dr. Akpor I. O.**

Department of Anatomical Pathology, College of Health Sciences, Benue State University Makurdi, NorthCentral Nigeria.

ABSTRACT

Carcinoma of the breast in a male is quite a rare occurrence. However, the risk factors, the pathologic features and prognostic factors documented for male breast carcinoma are remarkably similar to what obtains in women affected by the disease. In addition to assessing and confirming the patient-specific risk factors, and clinical presentation, a definitive diagnosis can be made by subjecting a needle core biopsy specimen or even a modified radical mastectomy specimen together with dissected axillary lymph nodes to histopathological evaluation. We report a case of an invasive ductal carcinoma of the breast in a 63 year old male who presented with a recurring and progressive right breast mass on account of the rarity of this diagnosis in males. The patient had a modified radical mastectomy and the mass with dissected lymph nodes was subjected to histopathological analysis upon which a diagnosis of mucinous invasive ductal carcinoma was made. Immunohistochemical tests were done to further characterize the tumour, which was found to be positive for the oestrogen receptor. The patient was placed on tamoxifen post operatively and is alive and symptom free as at the time of this report.

KEYWORDS: Male breast cancer; Invasive ductal; Mucinous Carcinoma.

INTRODUCTION

The incidence of breast cancer in men is only about 1% of that in women, translating to a lifetime risk of 0.11%,[1,2] Risk factors in men are similar to those in females and include; increasing age, exposure to exogenous oestrogens, ionizing radiation, first degree relatives with breast cancer, obesity, infertility, and residency in western countries. Klinefelter syndrome, and decreased testicular function are aetiological associations in 3 to 8% of cases, while an additional 4 to 14% of male breast cancer cases are attributed to germline mutations of the BRCA-2 gene.[1,2,8] In families with at least one affected male, there is a 60% to 76% chance of a BRCA-2 gene mutation[1]. In a review by Fentiman,[3] other sources of risk cited include working in occupations that expose the patient to extremely hot environments like blast furnaces, steel works and rolling mills; soaps, perfume, petrol or exhaust fumes. According to the same author, the consumption of alcohol by as much as 10gm daily increases the risk of male breast cancer developing by 16%.[3]

The typical age at diagnosis is between 60 and 70 years.[1,3] The epithelium in the male breast is limited to large ducts near the nipple, so carcinomas present often as a palpable subareolar mass with nipple discharge.[1] The lesion is usually close to the overlying skin and underlying thoracic wall, therefore even the smaller tumours can invade these structures and cause ulceration. The major susceptibility genes for familial breast carcinomas are all tumour suppressor genes, having their roles or functions in the repair of damaged DNA and the maintenance of genomic integrity. They are the BRCA-1, BRCA-2, TP53, and CHECK-2 genes.[1]

Apart from the non-special type invasive ductal carcinoma (IDC) being the most common histological variant, other special histologic types are described including the papillary, mucinous (or colloid), medullary, tubular, secretory, adenoid cystic carcinoma types, et al.[1,2,8] The same systemic treatment guidelines are employed for both men and women affected by this malignancy. Most breast cancers are treated locally by performing a mastectomy. Hormone receptor expression, particularly the estrogen receptor (ER) is relatively high in male breast cancer tissue.[8] Therefore adjuvant hormonal therapy is of great value in the treatment of MBC.[8,18] The purpose of this report is to document and communicate the quite rare diagnosis of an invasive

ductal carcinoma of the breast, mucinous variant in a male patient who has done well with hormone based adjunct treatment.

CASE REPORT

M.A is a sixty three-year old male, who presented to the General Surgical Outpatient Department of the Benue State University Teaching Hospital (BSUTH), Makurdi with a complaint of a recurrent right breast mass of five years duration at the time of presentation. This mass was painless, and progressively increased in size, and the increase became even more rapid four months prior to presentation and the performance of mastectomy. Earlier in the course of the disease, a linear ulcer appeared on the skin overlying the mass that began to discharge minute amounts of blood which stained the patient's clothes, but the bleeding stopped eventually. There were no records of a family history of breast cancer, of exposure to ionizing radiation, or of trauma to the breast in question.

Physical examination findings showed that the patient is an obese middle-aged man with a firm non-tender mass encompassing the whole of the right breast, and measuring 28cm x 32cm. The mass had cystic areas and was multi-lobulated, being attached to the overlying skin, but not to the underlying chest wall.

A needle core biopsy sample was taken, and sent for histopathological evaluation at the Histopathology laboratory of the Department of Anatomical pathology of the same hospital, following which a diagnosis of invasive ductal carcinoma of the right breast mucinous variant was made (Fig. 1). In addition, ancillary immunohistochemical assays were done on the tissue blocks prepared from the tumour to assess the hormone receptor status, which were specifically oestrogen receptor, progesterone receptor, and the human epidermal growth factor-2 (HER-2/neu) receptor.

The immunohistochemistry tests revealed the lesion to be positive for only the oestrogen receptor (ER) (see Fig. 2), where as the progesterone receptor (PR) and HER-2 tests were both negative.

A right mastectomy and axillary lymph node clearance were performed on this patient, and he was placed post operatively on Tamoxifen 20mg (hormonal therapy) per oral, daily for four months. He was also, subsequently worked up for adjuvant chemotherapy and possible radiotherapy, while being discharged.

The grossly large tumour size in this patient, which is one of the poor prognostic factors for breast cancer is clearly recognized. However, one and half years post mastectomy and hormonal therapy, this patient had attested to a significant improvement, absence of symptoms and none recurrence of disease.

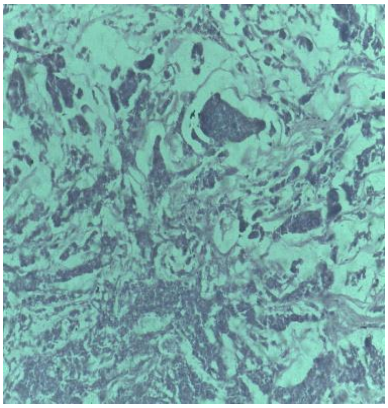

Fig. 1: Histological Features of Mucinous Invasive ductal carcinoma. Pools of mucin surround the neoplastic epithelial cells, showing pleomorphic hyperchromatic nuclei. *(10* x *obj.Magn.Haematoxylin & Eosin).*

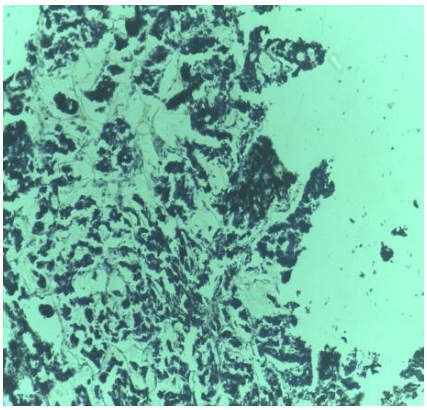

Fig. 2: Oestrogen Receptor Positive Ductal carcinoma. The image shows cytoplasmic and nuclear staining for oestrogen receptor in the maligant cells. *(10* x *Obj. Magn.Immuno).*

DISCUSSION

The incidence of invasive carcinoma of the breast in men is only 1% of the incidence in women, which translates to a lifetime risk of 0.11%,[1] thus establishing the rarity of this disease in men. Literature on male breast cancer (MBC) is quite sparse and a few published studies and reports give further confirmation of this. The risk factors for carcinoma of the breast in a male as documented are similar to those in women and include among others, increasing age, exposure to exogenous oestrogens, family history (in first degree relatives) and obesity.[1,9,21] According to Fentiman,[3] 20% of cases of male breast cancer give a family history. In the index case, there was no documented family history nor the history of exposure to exogenous oestrogens for any possible reason; the only documented risk factor is obesity, and the patient's age at the time of diagnosis of 63 years, which corroborates with what obtains in already published literature.[1,2,3] Other risk factors, although poorly understood include, exposure to high ambient temperatures and exhaust fumes, and to occupations involving working with soap, perfume, and petrol.[3,4]

The typical age at presentation is 60 to 70 years, with a median age of 65 years and some studies have shown that it presents or is diagnosed at a slightly older age (about a decade later) than in females and presents with a higher histological grade or stage compared to its counterpart in the female.[1,3,4] Other clinical features include, a palpable subareolar (or retroareolar) mass, usually 2 to 3 cm in size, nipple bleeding or discharge, and ulceration of the skin over the tumour.[1,2,3,4] Male breast cancer generally presents at a more advanced stage, and with more lymph node metastases at the time of diagnosis when compared to female breast cancer, and this is common because men are basically unaware of the fact that breast cancer is a possibility in them.[4] The findings in the case we report are consistent with this pattern of presentation although, the patient had no lymph node involvement.

The frequencies of breast quadrants involved are 50% in the upper lateral quadrants, 20% in the central (subareolar) quadrant, and 30% in the other quadrants.[4] The two cases reported by Rodrigues and coworkers, and indeed majority of the cases reviewed had the breast masses located in the subareolar region, associated axillary lymphadenopathy, and the older patient (67 years) had an ulcer overlying the tumour of a diameter 2cm, while the younger patient (45 years) had a larger tumour of a diameter 8cm.[4] The index case however, had a mass that had destroyed the nipple-areola complex, was much larger and encompassed the entire right breast, at a size measuring 17x14x12.5cm (see Table 1 below). It also had a linear ulcer on the overlying skin which discharged modest amount of blood before that was stayed, but no other discharge from the nipple was experienced. Table 1 below is a summary of the cases of male breast cancer reviewed in this report.

Table 1: Review of the literature on male breast cancer.

Author	Year	Age (years)	Tumour Location	Size (cm)	Duration	Subtype	IHC Profile	Recurrence
Giordano[8]	2005	67.0	Subareolar	2 - 5	NA	IDC Unclassified	ER, PR	None
Rachid et al[16]	2009	52.8	Subareolar	NG	NA	IDC, Almost all others seen	Not done	Local recurrence in one patient
Olu-Eddo et al[14]	2010	64.4	NG	NG	---	IDC		None
Ezeome et al[17]	2010	60.5	NG	NG	---	IDC(65%)	Not done	None
Bourhafour et al[13]	2011			NG	NA			None
Baojiang et al[10]	2012	58.0	NG	NG	11 months (mean)	IDC	Not done	None
Ahmed et al[25]	2012	59.0± 2.3	NG	13± 2.5		IDC, ILC, Papillary	Not done	Recurrence in 29.8% after chemotherapy
Rodrigues et al[4]	2013	45.0, 67.0	Both subareolar	8, 2	NA	Papillary IDC, IDC NST	ER, PR	None
Hong et al[7]	2015	66.0	---	2	NA	IDC	ER,PR, HER-2	Recurrence occurred
Serdy et al[5]	2017	65	NG	2.3	NA	IDC, DCIS	ER, PR, HER-2	None
Present case, Akpor et al	2019	63	Multiple quadrants	17.0x14.0x12.5	5 years	IDC-Mucinous	Only ER positive	None

Keys: DCIS- ductal carcinoma in situ, ER- oestrogen receptor, HER- human epidermal growth factor receptor, IDC- invasive ductal carcinoma, IHC- immunohistochemistry, ILC- invasive lobular carcinoma, NA- not available, NG- not given, NST- none special type, PR- progesterone receptor.

In a cohort of sixty-one cases seen over a ten year period in the USA, a median age of 65 years, and a median invasive tumour size of 2.2cm were reported (Serdy et al.[5]). Whereas 48% (29 cases) of the cohort were lymph node positive, 42% were lymph node negative and the majority (87%) are of the histologic variant, non-special type invasive ductal carcinoma. Furthermore the immunohistochemical profile was similar to that of female breast cancer, with 97% being positive for ER, 95% androgen receptor positive, and 90% PR positive. In another review, male breast cancer accounts for only 0.7% of all breast cancer diagnoses and at a mean age of 67 years.[8] This author reported a painless subareolar lump, nipple retraction and bleeding as part of the clinical features, and that lymph node involvement imparts a 50% higher risk of a poor prognosis relative to absence of lymph node disease. Invasive ductal

carcinoma unclassified (non-special type) is identified as the most common histological pattern.[5,8] Other rarer histological types are the medullary, mucinous, papillary, tubular, and even adenoid cystic carcinoma and others.[8,16]

The patient in our report had the invasive ductal carcinoma, mucinous subtype which is characterized by sheets, nests and strands of neoplastic breast epithelial cells invading and destroying the stroma, and there are areas with extracellular mucin surrounding the malignant cells (see Fig 1). The atypical tumour cells appear markedly pleomorphic with enlarged, hyperchromatic, variably sized nuclei, and minimal tubule formation was seen in some foci. Abnormal mitotic figures were however abundant, and resection margins showed evidence of tumour cells, whereas the lymph nodes were free of tumour involvement.

What is the significance of delineating pure mucinous and other subtypes of IDC? It is observed that prognosis varies in proportion with the quantity of mucoid substance found in the tumour.[17,22,23] Most studies have established its favourable outcome, and this is probably due to the low frequency of lymph node metastasis and corresponding consistency in ER expression.[8,17,18,20,21,22,24] It is noteworthy that psammoma bodies (calcifications) were found in one case of mucinous carcinoma (Pillai et al[23]), a rather unusual feature of papillary type carcinomas. Immunohistochemistry showed the index tumour to be positive for only the oestrogen receptor, and negative for progesterone and epidermal growth factor receptors (see the figures 1 and 2). This as expected has an impact on the response of the disease to adjuvant hormone therapy usually tamoxifen (an oestrogenic analogue), since many studies have positively implicated oestrogen as a growth factor in breast cancer.[22,24] Baojiang and co workers[10] in China observed that male breast cancer patients had a worse prognosis generally, compared to female breast cancer patients, which may be due to a deficit in accessing adjuvant chemotherapy and endocrine therapy among male patients. The poorer prognosis is also confirmed by other researchers. They had observed tumour size, lymph node status and cancer stage as prognostic factors and all 42 cases in their cohort were diagnosed histologically as invasive ductal carcinoma-unclassified.

The highest rates of MBC (male breast cancer) are seen among Jewish men at 2.3/100,000,[3] and other authors have consistently shown that on the whole, the highest age adjusted rates for MBC are seen in Israel (at 1.08/100,000 man-years).[2,3,11] Ly also reported the lowest rates in Thailand and then Japan (at 0.14 and 0.17 per 100,000 respectively) and Fentiman observed the MBC rate in Japan to be less than 0.5/100,000 where the female breast cancer incidence is also low, if not the lowest.[3,11] The explanation for such variation in rates may partly be that there is population specific genetic susceptibility. For example among the Ashkenazi Jewish population, three founder mutations of the breast cancer associated genes, BRCA1 (two mutations of this gene) and BRCA2 (one mutation) are observed at higher frequencies compared to the general USA population.[11,12] Hence, given similar age-specific incidence patterns, similar prognostic factors and distribution, there is a suggestion that male breast cancer may aetiologically parallel or be similar to female breast cancer of late onset. Bourhafour et al.[13] reported 127 cases whose median age was 62 years and main symptom of retroareolar mass was recorded in 93.5% of cases. Since the male breast does not have lobular elements, the infiltrating ductal carcinoma is the dominant histological pattern as seen in 96% of cases in their cohort as well as in our report, and while ER and PR were both positive in 64% of patients.

A clinicopathological study in Western Nigeria showed the age range to be 35 to 90 years with a mean age of 64.4 years, and 87.5% of the cases presented with a self detected lump (Olu-Eddo et al).[14] The mean age corresponds with that of the patient in our report. Ulceration was seen in 68.8%, nipple discharge in 43.8% and nipple bleeding in 25.0% and invasive ductal carcinoma was the main histological type as seen in about 82%. This study concluded that male breast cancer is rare and the patients present late with advanced disease. Dauda et al,[15] in North-eastern Nigeria put the male to female ratio for breast cancer at 1:24, substantiating the rarity of this condition in male subjects. The mean age at diagnosis was in the range, 41 to 60 years for male patients in their study, which is lower than the age of the case in our report. Both West African studies (Dauda et al,[15] Rachid et al,[16]) identified invasive ductal carcinoma NST again as the most common histologic variant in all male and female breast cancers. Ezeome et al,[19] gave a frequency of 2% in Eastern Nigeria, age range of 25 to 84 years and mean age of 60.5 years. They also reported invasive ductal carcinoma NST in 65% of cases studied.[19] Ahmed et al,[25] studied 57 cases of MBC in North Western Nigeria, and found their mean age to be 59.0 ± 2.3 years, with papillary, and combined invasive ductal and lobular carcinoma as histopathological patterns seen. The age range of their patients is consistent with that of our patient, but they had no receptor tests done for them.

CONCLUSION

Invasive ductal carcinoma of the breast is largely a diagnosis of women, but is also a possibility in men as shown in this report. We have presented a case of a malignant breast lesion in a man which turned out to be the mucinous type invasive ductal carcinoma, though the non-special type invasive ductal carcinoma is stably the commonest histologic variant. Hormone receptor assay is beneficial, both therapeutically and for prognostication.

RECOMMENDATION

We advocate that larger and more sponsored studies on breast cancer in men be conducted in order to better understand the clinicopathological characteristics and to develop effective standard treatment protocols for it.

Conflict of interest

No conflicting interests are declared by the authors.

Consent

Informed consent was duly sought and obtained from the patient to have this report published.

REFERENCES

1. Lester SC. The Breast In: Kumar V, Abbas AK, Aster JC, editors. Robbins and Cotran Pathologic Basis of Disease, 9th ed. Philadelphia: Elsevier-Saunders, 2015; 1066-1068.
2. Rosen PP. Carcinoma of the male breast. In: Rosen's Breast pathology, 3rd ed. Lippincot Williams & Wilkins, 2009; 787-801.
3. Fentiman IS. Male breast cancer: a review. Available online from ecancermedicalscience.ecancer [Internet]. 2009 Mar 20; 3: 140.
4. Rodrigues FR, da-Silva AV, Teixeira CM, Antunes SC, Rochael MC. Two cases of male breast cancer at a University hospital in southeast Brazil. Int Journ Gen Med, 2013; 6: 503-505.
5. Serdy KM, Leone JP, Dabbs DJ, Bhargava R. Male breast cancer; A single institution clinicopathologic and immunohistochemical study. Amer Journ Clin Pathol, 2017; 147: 110-119.
6. Deb S, Lakhani SR, Ottini L, Fox SB. The cancer genetics and pathology of male breast cancer. Histopathology, 2016; 68: 110-118.
7. Hong JH, Ha KS, Jung YH, Won HS, An HJ, Lee GJ. Clinical features of male breast cancer: Experiences from Seven institutions over 20 years. Cancer Res Treat, 2016; 48: 1389-1398.
8. Giordano SH. A review of the diagnosis and management of male breast cancer. The Oncologist, 2005; 10: 471-479.
9. Yalaza M, Inan A, Bozer M. Male breast cancer. J Breast Health, 2016; 12: 1-8.
10. Baojiang L, Tingting L, Gang L, Li Z. Male breast cancer; A retrospective study comparing survival with female breast cancer. Oncology Letters, 2012; 4: 642-646.
11. Ly D, Forman D, Ferlay J, Brinton LA, Cook MB. An International comparison of male and female breast cancer incidence rates. Int J Cancer, 2013; 132(8): 1918-1926.
12. Struewing JP, Hartge P, Wacholder S, Baker SM, Berlin M, McAdams M et al. The risk of cancer associated with specific mutations of BRCA1 and BRCA2 a mong Ashkenazi Jews. N Engl J Med, 1997; 336: 1401-1408.
13. Bourhafour M, Belbaraka R, Souadka A, M'rabti H, Tijami F, Errihani H. Male breast cancer; a report of 127 cases at a Moroccan institution. BMC Res Notes, 2011; 4: 219-224.
14. Olu-Eddo AN, Momoh MI. Clinicopathological study of male breast cancer in Nigerians and a review of the literature. Nig Q J Hosp Med, 2010; 20(3): 121-124.
15. Dauda AM, Misauno MA, Ojo EO. Histopathological types of breast cancer in Gombe, north eastern Nigeria; a twelve year review. Afr Jour Reprod Health, 2011; 15(1): 107-109.
16. Rachid S, Yacouba H, Hassane N. Male breast cancer; 22 case reports at the National hospital of Niamey-Niger (West Africa). The Pan African Medical Journal.[Internet], 2009 Nov 16; 3: 15-22. Available from: http://www.panafrican-med-journal.com/content/article/3/15/full.
17. Rosen PP. Mucinous Carcinoma. Rosen's Breast Pathology, 3rd ed. Philadelphia: Lippincott Williams & Wilkins, 2009; 515-533.
18. Jaiyesimi IA, Buzdar AU, Sahin AA. Carcinoma of the male breast. Ann Intern Med, 1992; 117: 771-777
19. Ezeome ER, Emegoakor CD, Chianakwana GU, Anyanwu SN. The pattern of male breast cancer in eastern Nigeria; a 12 year review. Niger Med J., 2010; 51: 26-29.
20. Zabolotny BP, Zalai CV, Meterissian SH. Successful use of letrozole in male breast cancer: a case report and review of hormonal therapy for male breast cancer. J Surg Oncol, 2005; 90: 26-30.
21. Albo D, Ames FC, Hunt KK, Ross MI, Singletary SE, Kuerer HM. Evaluation of lymph node status in male breast cancer patients: a role for sentinel lymph node biopsy. Breast Cancer Res Treat, 2003; 77: 9-14.
22. Rosen PP, Menendez-Botet CJ, Urban JA, Frachia A, Schwartz MK. Estrogen receptor protein (ERP) in multiple tumour specimens from individual patients with breast cancer. Cancer, 1977; 39: 2194-2200.
23. Pillai KR, Jayasree K, Jayalal KS, Mani KS, Abraham EK. Mucinous carcinoma of breast with abundant psammoma bodies in fine needle aspiration: A case report. Diagn Cytopathol, 2007; 35: 230-233.
24. Lesser ML, Rosen PP, Senie RT, Duthie MA, Menendez-Botet C, Schwartz MK. Estrogen and progesterone receptors in breast carcinoma; Correlations with epidemiology and pathology. Cancer, 1981; 48: 299-309.
25. Ahmed A, Ukwenya Y, Abdullahi A, Muhammad I. Management and Outcomes of Male Breast Cancer in Zaria, Nigeria. International Journal of Breast Cancer Article ID845143, 2012; 6.